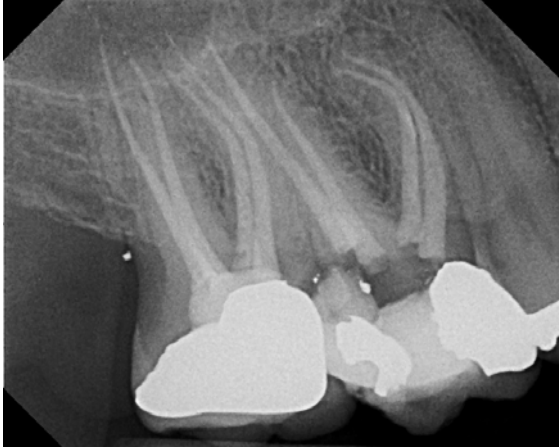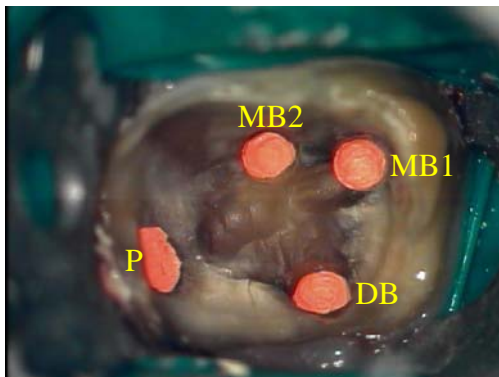


**Second MB Canal– MB2**



**MB2**

- An additional canal is often found in the MB root of Max molars
- Studies report the additional canal (MB2) is present in 51-96% of Max molars
- MB1 & MB2 can merge but studies report separate apical foramina in 50% of cases
- Access prep must be rhomboidal in shape, not the typical triangular access
- MB2's orifice is usually more mesial and lingual than MB1
- Must assume MB2 to be present in every maxillary molar until proven otherwise



Endodontic treatment and photographs by  
George Brown, Jr, DMD, MSD

1401 Georgian Park • Suite 100 • Peachtree City, GA 30269  
Phone: 770-631-2728 • Email: info@ptendo.com